CRANIO-CEREBRAL TOPOGRAPHY—No. 6.

A COMPOSITE VIEW HAS BEEN TAKEN TO SHOW THE RELATION OF THE SURFACE LINES AND OF THE SUTURES TO THE PRINCIPAL FISSURES AND CONVOLUTIONS.

In viewing the relationships in this subject, aged 5 years, it should be borne in mind that the fissures of the brain of the child do not in all cases bear the same relationship to the cranial sutures as do those of the adult. Important differences exist, especially in the fissure of Sylvius, associated mainly with differences in the proportionate sizes of different lobes of the brain

This view should therefore be compared with the relations shown in the corresponding view of the adult head (No. 10).

At birth the **Sylvian fissure** lies above the squamo-parietal suture, but the fissure and the suture approach one another rapidly up to the fifth year, and at that age the fissure lies about 14 millimetres above the suture. In the adult, the fissure may lie above, below, or subjacent to the fissure. Chiene's surface lines drawn upon the head of the child also place the **Sylvian** point above the suture, but the fissure lies at a slightly higher level even than this point.

The **fissure of Rolando** maintains, after birth, a very constant position in relation to the surface, both at its upper and its lower ends.

Comparing the lettering in No. 1, it will be seen that the **Rolandic area** lies inside a quadrilateral figure, ACDM, but it must be noted that the true motor area is confined to the precentral area, and does not exten behind the fissure of Rolando. The letters L, A, F, indicate, in a general way, the parts which contain the motor centres for the lower limb, arm and face respectively in the ascending frontal convolution.

The figure 2 is placed on the division of the Sylvian fissure, and, as has been pointed out, in the child this division lies at a slightly higher level than the surface mark which would indicate its position in the head of the adult. The line AC however overlies the posterior horizontal limb of the Sylvian fissure, and a finger's breadth below that line lies the *parallel fissure*, 3, the hinder end of which is continued upwards into the parietal lobe to the region marked 8, subjacent to the point B in the surface lines, where lies the angular gyrus or centre for word vision. The letter B overlies the area which in the left hemisphere is the motor speech centre or Broca's convolution. The coronal suture can be seen to lie in front of the line AM and therefore is well in front of the fissure of Rolando.

The letters and figures indicate :—

L. Centre for opposite lower limb.
A. Centre for opposite upper limb.
F. Centre for opposite side of face.
S. Supra-marginal convolution.
V. Visual centre (sensory).
B. Broca's convolution.

H. First temporal convolution.
1. Fissure of Rolando.
2. Division of Sylvian fissure.
3. Parallel (1st temporal) fissure.
4. Angular gyrus.

CARD NO. 6
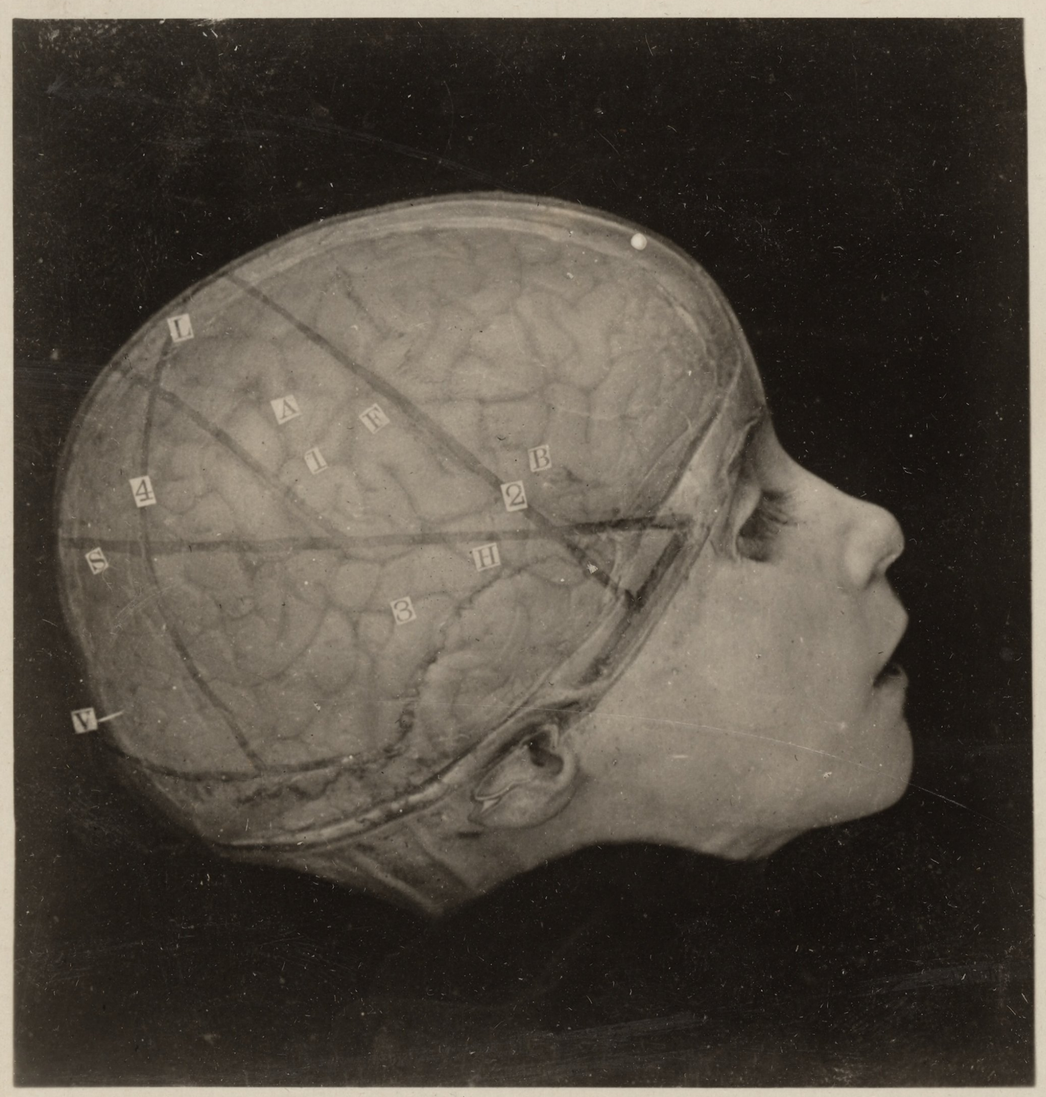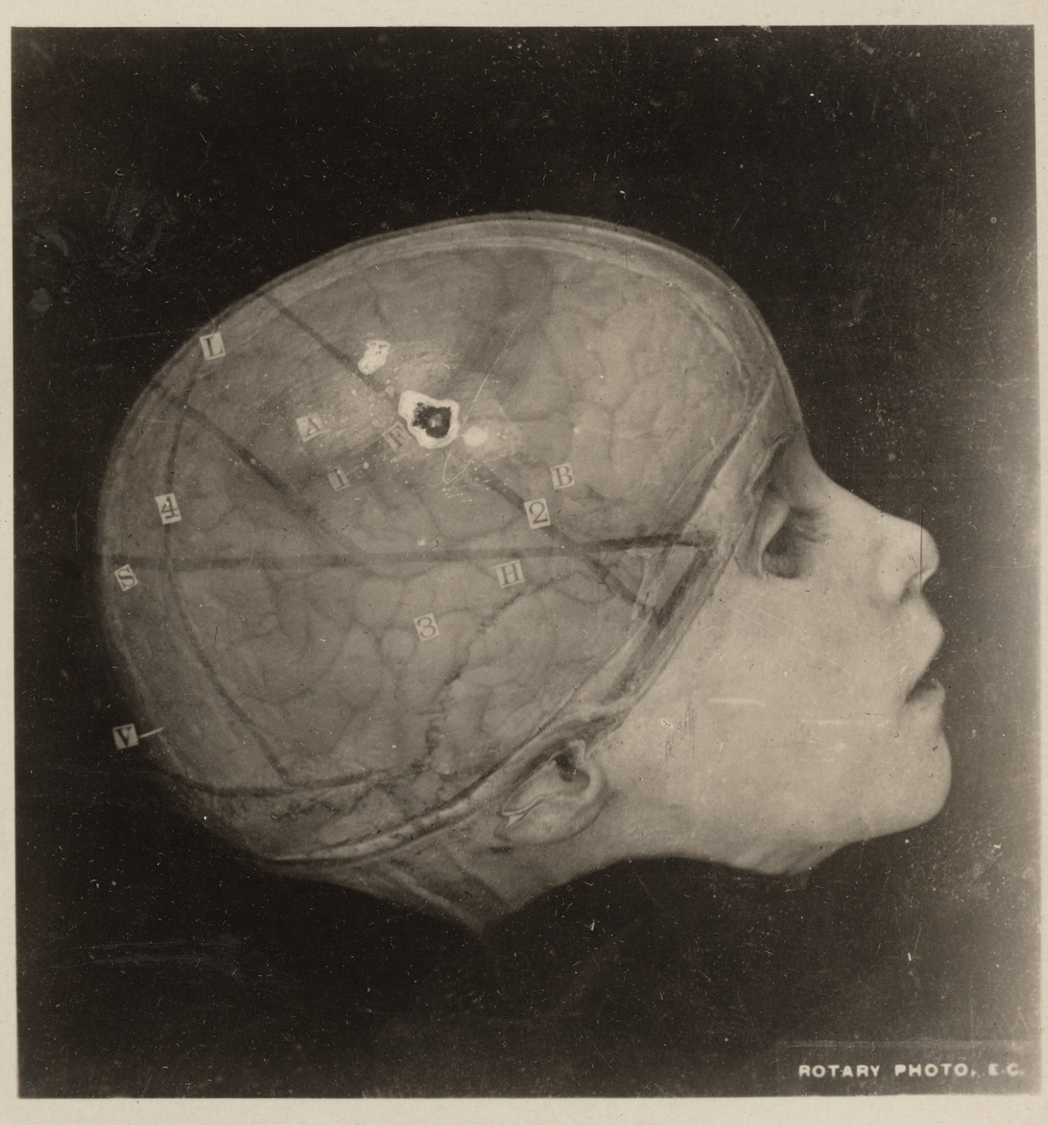
SECTION I