CRANIO-CEREBRAL TOPOGRAPHY—No. 2.

THE SCALP HAS BEEN REMOVED FROM THE SURFACE OF THE CRANIUM OVER THE AREA PREVIOUSLY MARKED OUT AND THE SUTURES ARE SHOWN.

These sutures are, mostly, of limited value as landmarks for parts of the brain, but their position must be borne in mind in order that the line of a suture may not be mistaken for a fissured fracture of the skull in cases of injury to the head.

The principal sutures are :—

1. The **coronal**, between the frontal and parietal bones, which passes transversely across the head, but is in front of the midpoint M.

2. The **lambdoidal** suture, between the occipital and parietal bones.

3. The **spheno-parietal** suture, between the anterior inferior angle of the parietal and the great wing of the sphenoid. It is known as the **pterion**, and it overlies the point of division of the Sylvian fissure into its three limbs, and the bifurcation of the middle meningeal artery, or its anterior division.

4. The **squamous** suture, between the parietal bone and the squamous part of the temporal, beginning at the pterion and arching back to the asterion, or junction of the parietal, temporal, and occipital bones. The highest part of this suture reaches up to the lower end of the fissure of Rolando.

The letters and figures indicate—

1. Coronal suture.
2. Pterion.
3. Squamous suture.
4. Asterion.
5. Parietal eminence.
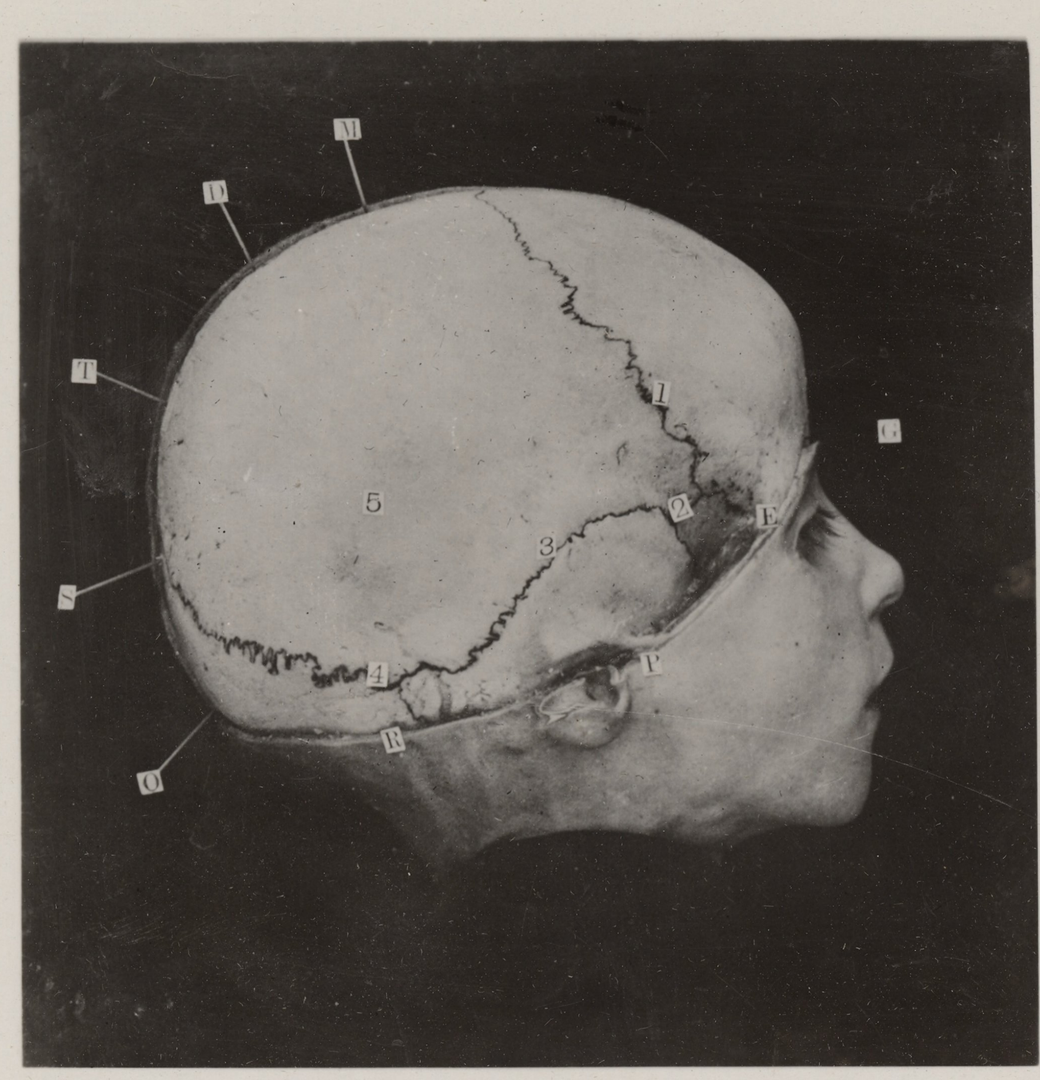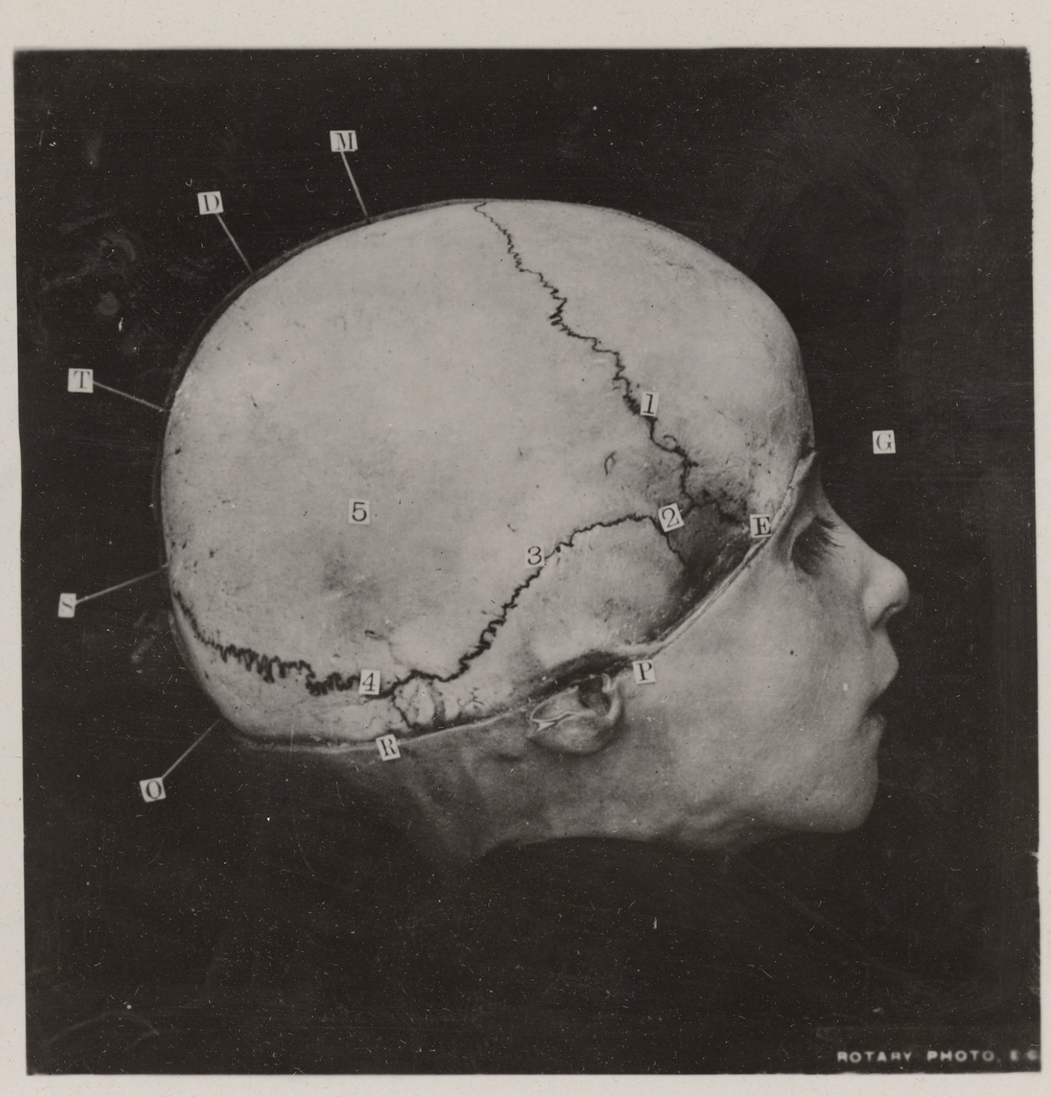
G. Glabella.
M. Midpoint between G and O.
T. Three-quarters point between G and O.
S. Seven-eighths point between G and O.
O. External occipital protuberance.
R. Midpoint between O and P.
P. Root of zygoma.
E. External angular process