CENTRAL NERVOUS SYSTEM.

BRAIN—No. 10.

TWO CORONAL SECTIONS THROUGH THE BRAIN.

A. In a plane corresponding to the anterior end of the caudate nucleus.

B. In a plane corresponding to the anterior part of the locus perforatus anticus.

Lettering common to both specimens.

---

1. Corpus callosum.
2. Rostrum of corpus callosum.
3. Anterior horn of lateral ventricle. In A, note how the genu of corpus callosum forms the anterior boundary of this ventricle.
4. Caudate nucleus.
5. Septum lucidum.
6. Anterior end of the internal capsule.
7. Putamen of the lenticular nucleus.
8. External capsule, and immediately to the outer side of this the thin lamina of gray matter termed the claustrum.

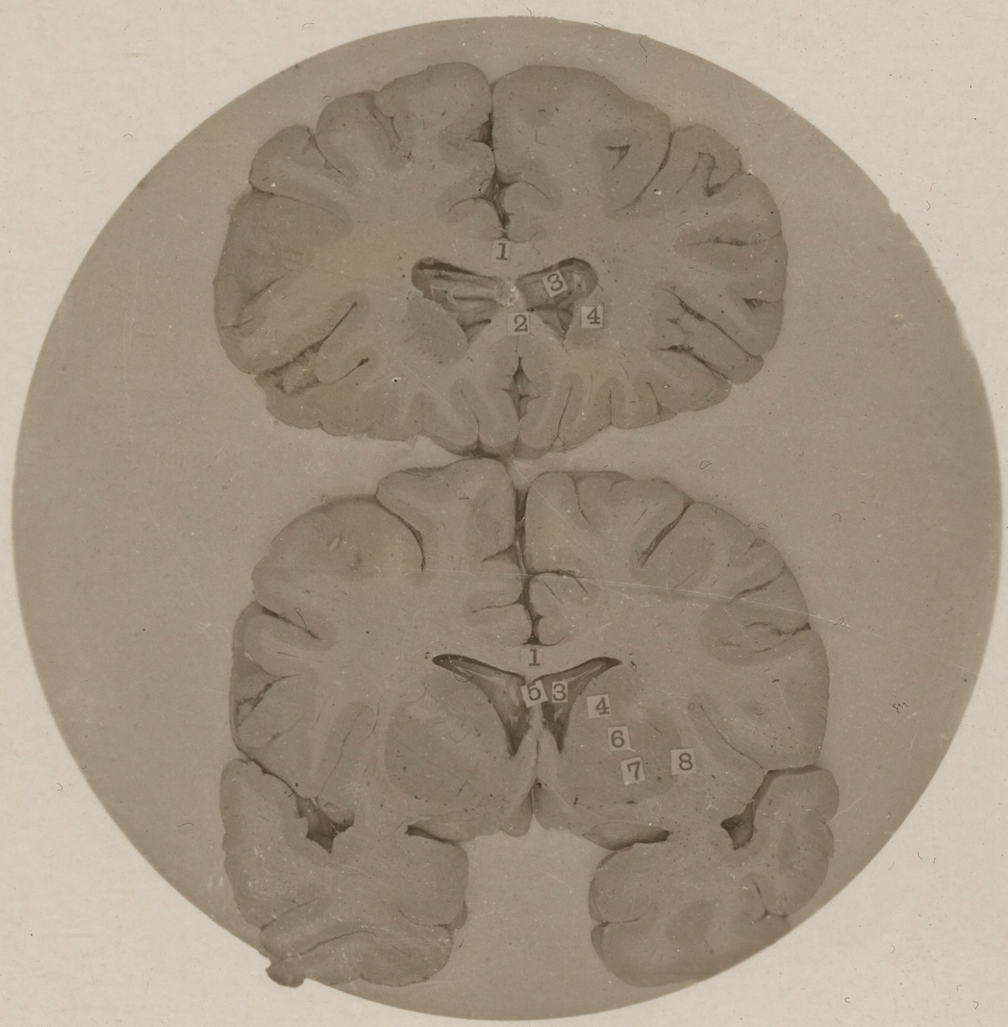

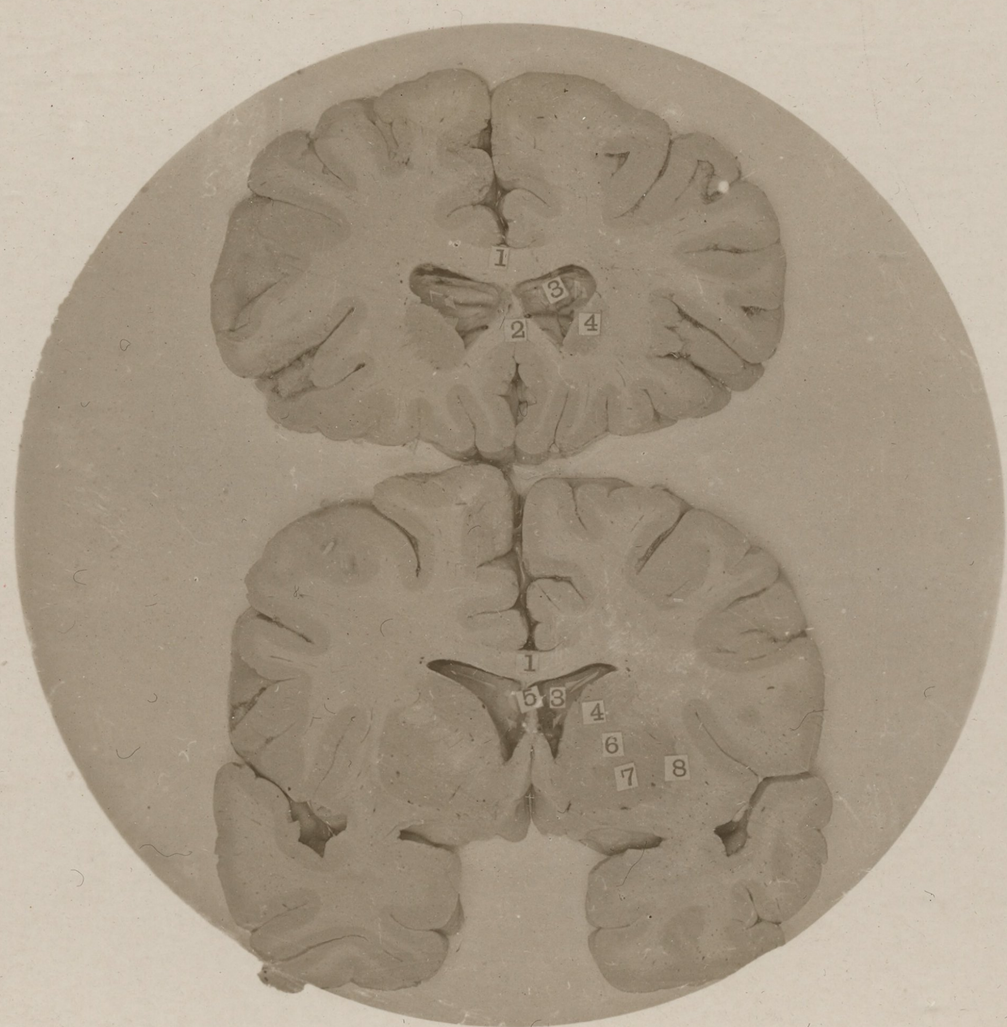

Copyright: T. C. & E. C. Jack, Edinburgh, & 34 Henrietta Street, London, W.C.