# ABDOMEN.

## MALE PELVIS.—No. 11.

IN ADDITION TO THE DISSECTION IN NO. 9, A PORTION OF THE RECTUM HAS BEEN REMOVED TO SHOW ITS ANTERIOR RELATIONS.

In front of the rectum lie the peritoneum in the upper part, and in the lower the recto-vesical fascia separating the rectum from the back of the bladder and prostate.

On this surface of the peritoneum can be seen a whitish area, gradually diminishing in size as it passes down, where the rectum was in contact with the peritoneal membrane.

The recto-vesical fascia is a part of the visceral pelvic fascia which encloses the seminal vesicles on each side, and passes across from one side to the other between the bladder and the rectum, forming a partition between them.

The sheath of the seminal vesicle of the left side has been opened, to show the way in which the fascia is arranged in relation to it.

The rectal fascia is a fairly strong layer of visceral pelvic fascia, which invests the lower portion of the rectum as it passes down between the levator ani muscles. It is continuous with the recto-vesical layer along the side wall of the pelvis.

The upper limit of the recto-vesical fascia and the termination of the contact of peritoneum and rectum are seen to be at the level of the spine of the ischium.

---

***The figures indicate—***

1. Sphincter ani.
2. Rectal fascia.
3. Rectum, lower end.
4. Recto-vesical fascia.
5. Peritoneum, area in contact with rectum.
6. Left seminal vesicle.
7. Rectum, upper end.
8. Parietal pelvic fascia, and origin of levator ani.
9. Great sacro-sciatic ligament.
10. Spine of ischium.
11. Third piece of sacrum, divided.

EDINBURGH: T. C. & E. C. JACK; AND 34 HENRIETTA STREET, LONDON, W.C.

MALE PELVIS. No. 11.

(EDINBURGH STEREOSCOPIC ANATOMY.)

Copyright: T. C. & E. C. Jack, Edinburgh, & 34 Henrietta St., London, W.C.

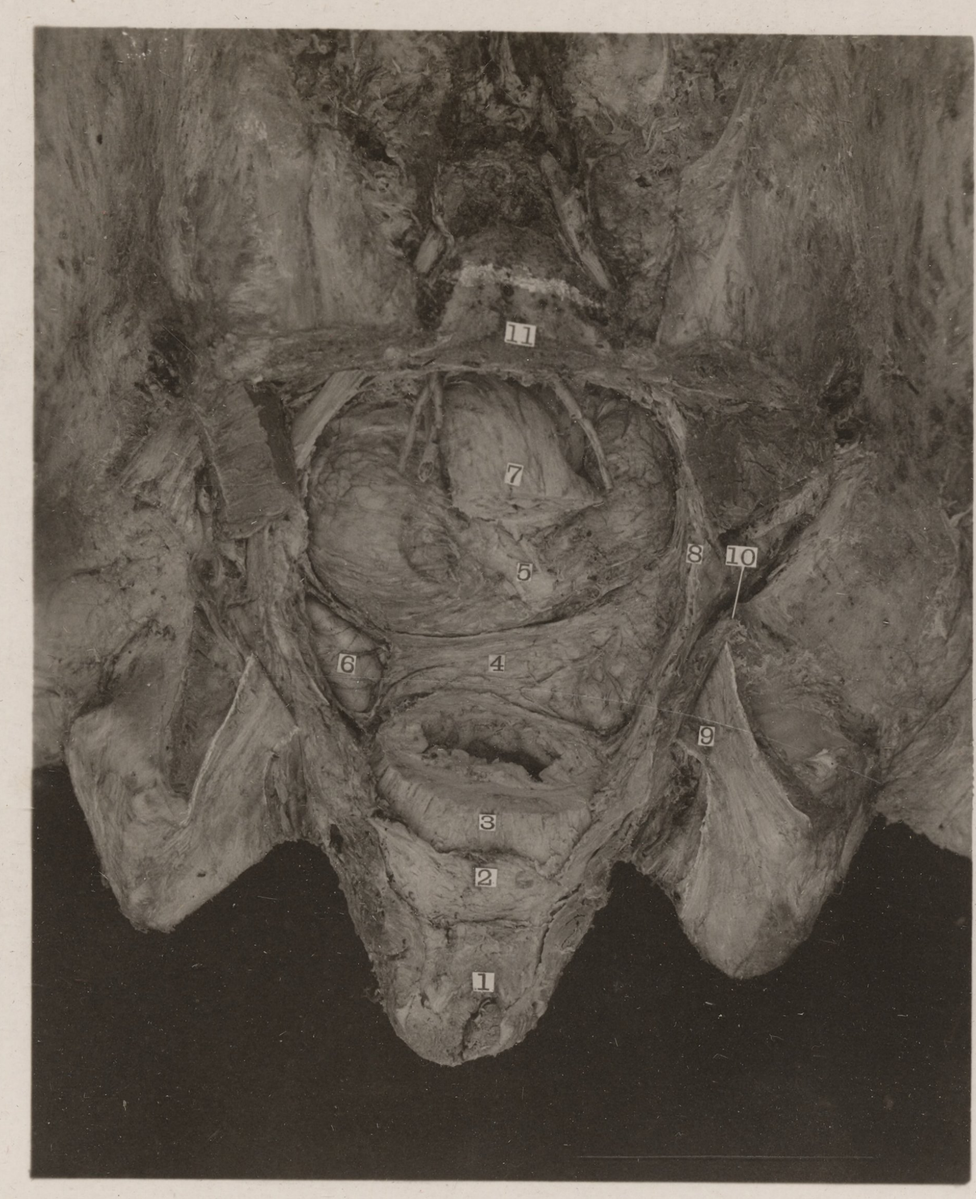


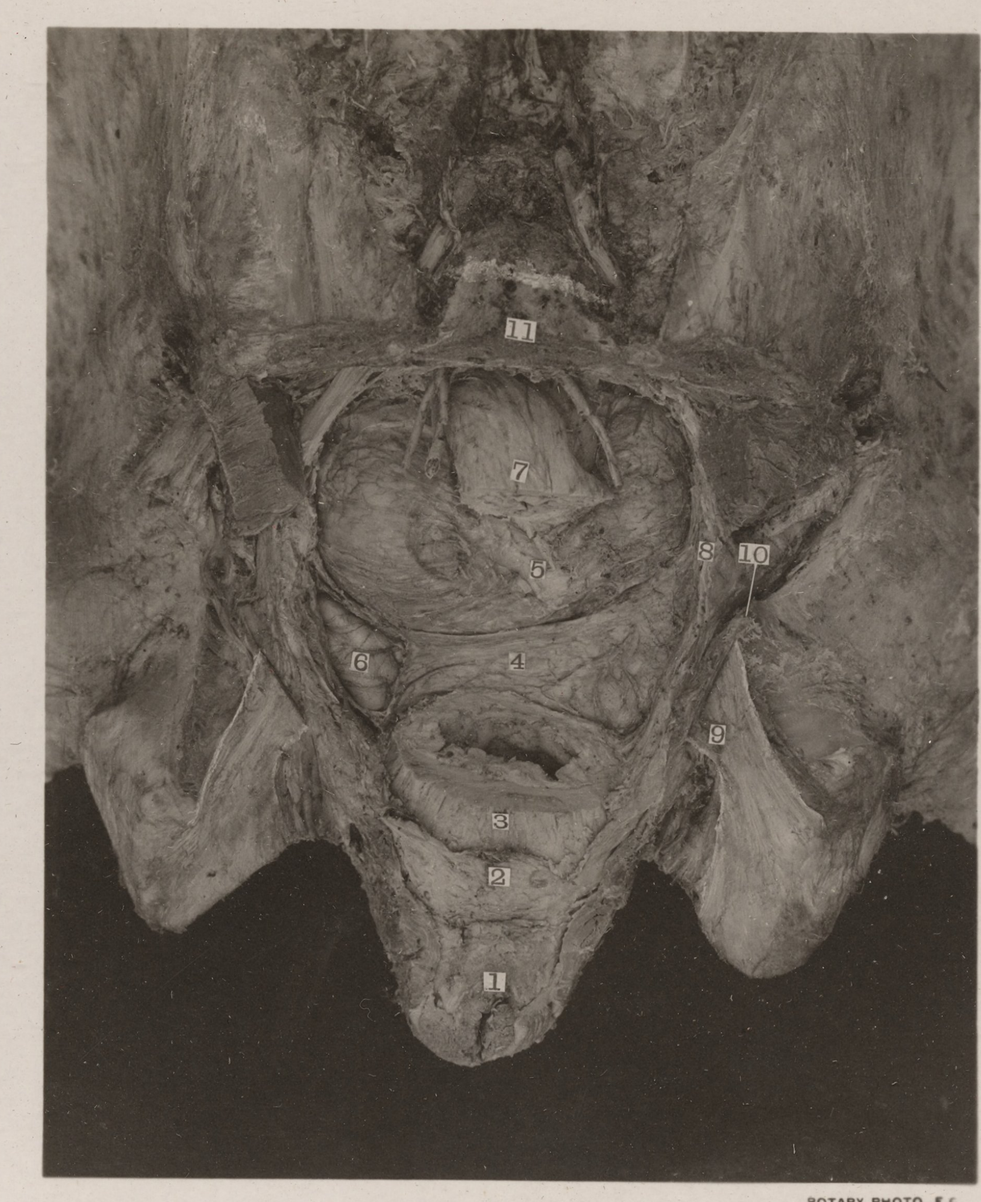


ROTARY PHOTO, E.C