COCHLEA RELATION TO OSSICLES AND MASTOID ANTRUM

SUPERIOR VIEW. The bony antral and tympanic tegmen has been removed in this specimen. The bodies of the malleus and incus are viewed from above. The superior half of the cochlea has been drilled away, demonstrating the position of the cochlea as it lies internal in the tip of the petrous portion of the temporal bone. The three tiers or turns of the cochlea are shown. Distance from the center of the cochlea to the ossicles, 16 m.m.; the same distance from the ossicles to the mastoid antrum. The superior surface of the carotid canal is just below the cochlea.

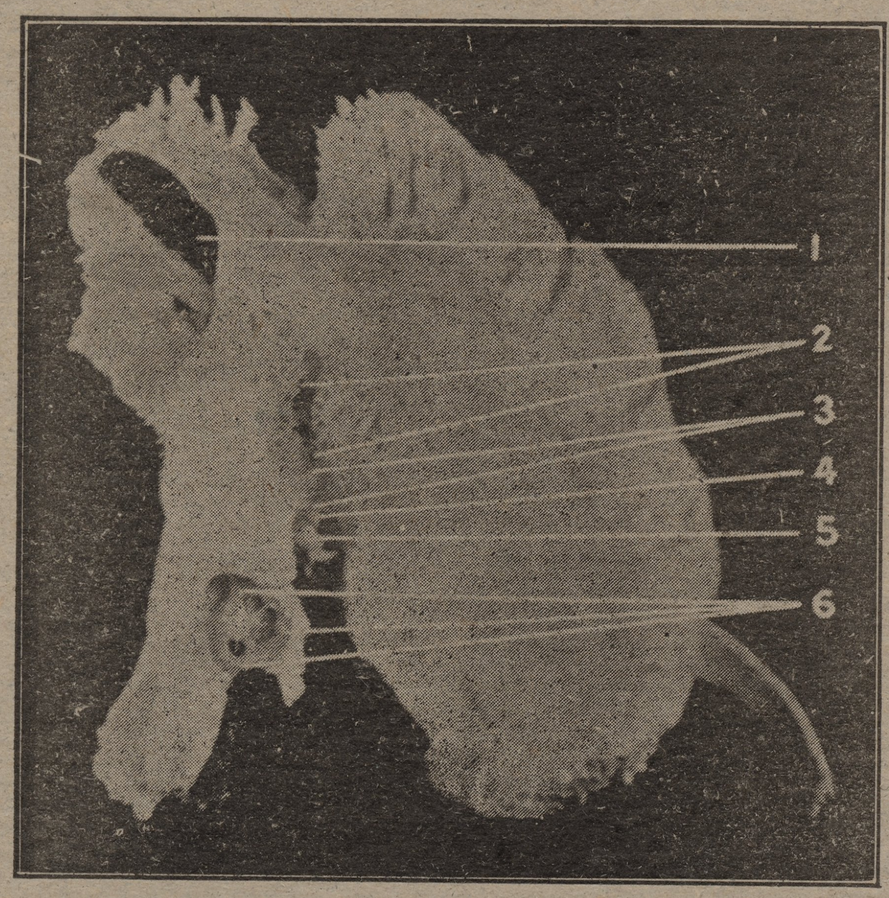

The figures indicate—

1—Lateral Sinus
2—Mastoid Antrum
3—Aditus Ad. Antrum
4—Incus (Body)
5—Malleus (Head)
6—Cochlea (three tiers or turns)

Copyrighted, 1911 by Imperial Publishing Co.

IMPERIAL PUBLISHING COMPANY - - - - - - NEW YORK