COCHLEA RELATION TO SEMICIRCULAR CANALS

SUPERIOR VIEW NO. 1. The entire internal superior surface of the petrous portion of the temporal bone is removed, exposing the floor of the mastoid antrum and inferior surface of the auditory canal. The external semi-circular canal is opened throughout its length, the superior sigmoidal turn of the superior semi-circular canal is demonstrated; also the external superior bony covering of the cochlea, giving its relation to the internal auditory canal and vestibule of the cochlea. The slit No. 6 passing from the region of the lateral sinus, below the mastoid cells, leading into the vestibule of the cochlea at the junction of the posterior internal turn of the superior and posterior semi-circular canals is the aquiductus vestibuli.

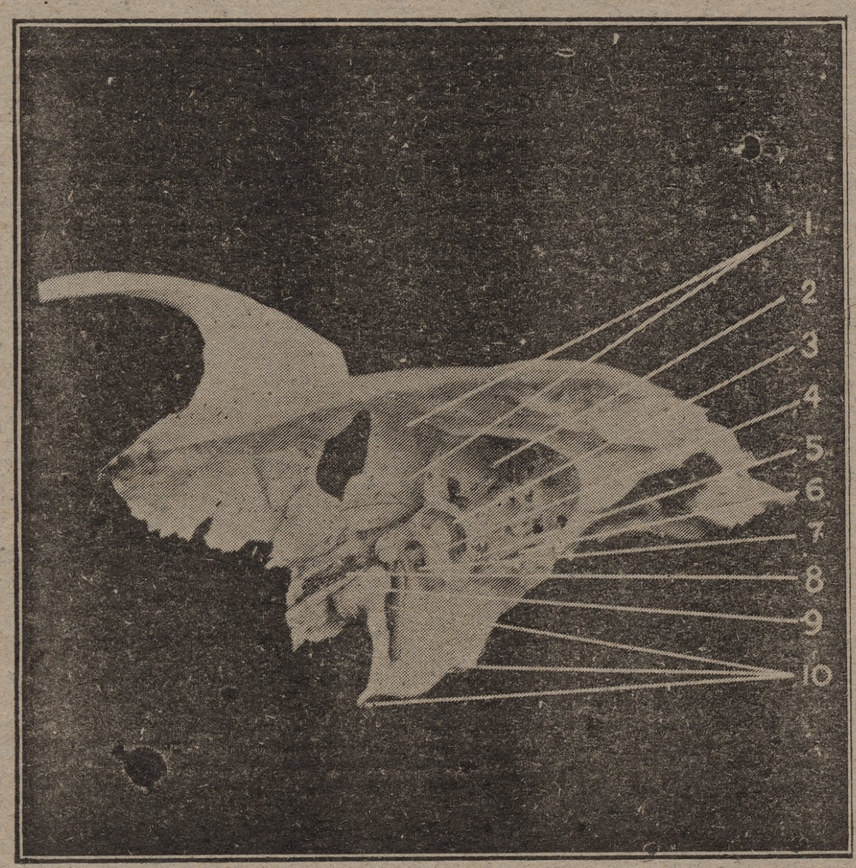

The figures indicate—

1—Auditory Canal (Floor)
2—Mastoid Antrum (Floor)
3—Ext. Semi-Circular Canal
4—Superior Semi-Circular Canal
5—Posterior Semi-Circular Canal
6—Aqueductus Vestibuli
7—Vestibule of Cochlea
8—Greater and Lesser Superficial Petrosal Nerve Canals
9—Superior Surface of Cochlea.
10—Internal Auditory Meatus

Copyrighted, 1911, by Imperial Publishing Co.

IMPERIAL PUBLISHING COMPANY - - - - - - NEW YORK