POSTERIOR TYMPANIC WALL RELATION—NO. 1

This section similar to that shown in stereogram No. 15 has been sawed perpendicularly through the posterior wall of the auditory canal to the depth of the descending facial canal, meeting a lateral sawing through the eustachian tube and annular ring. The ossicular chain, malleus, incus and stapes have been removed. The entire posterior tympanic wall surface with its projections and depressions and foraminæ are shown, especially the tympanic opening of the processus cochleariformis, through which the tendon of the tensor tympani mus. emerges. The pyramid of the tympanum is shown, No. 8. Through the opening at its apex the tendon of the stapedius mus. emerges. Through the narrow slit anterior and below the tip is the foramen of the chorda tympani nerve.

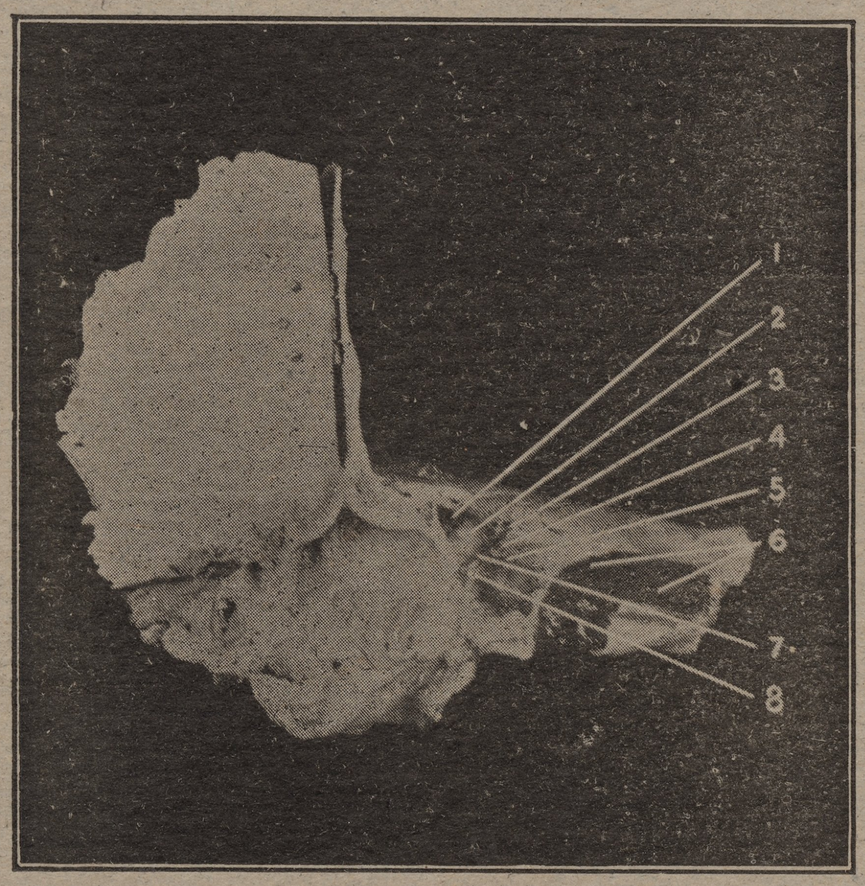

The figures indicate—

1—Mastoid Antrum Opening (Tympanic Mouth)
2—Prominence of Ext. Semi-Cir. Canal
3—Tympanic Foramen of Transverse Facial
4—Tip of Proc. Cochleariformis
5—Oval Window
6—Carotid Canal. Internal Surface
7—Transverse Facial Canal
8—Pyramid

Copyrighted, 1911, by Imperial Publishing Co.

IMPERIAL PUBLISHING COMPANY - - - - - - NEW YORK