ABDOMEN.

VISCERA—No. 20.

PANCREAS, BILE-DUCT AND DUCT OF PANCREAS, AND DUODENUM, VIEWED FROM BEHIND.

A shows the interior of the duodenum. A probe has been passed along the common bile-duct, and the orifice is seen to lie on the summit of a papilla.

In B, the common bile-duct is seen passing downwards behind the head of the pancreas, and is joined by the duct of the pancreas. In relation to the pancreas are seen, the origin of the *coeliac axis* artery which lies at its upper border, the *hepatic artery* passing from thence to the right and the *splenic artery* to the left along the upper border of the pancreas, the *superior mesenteric* artery and vein, and the *portal vein.*

The figures indicate—
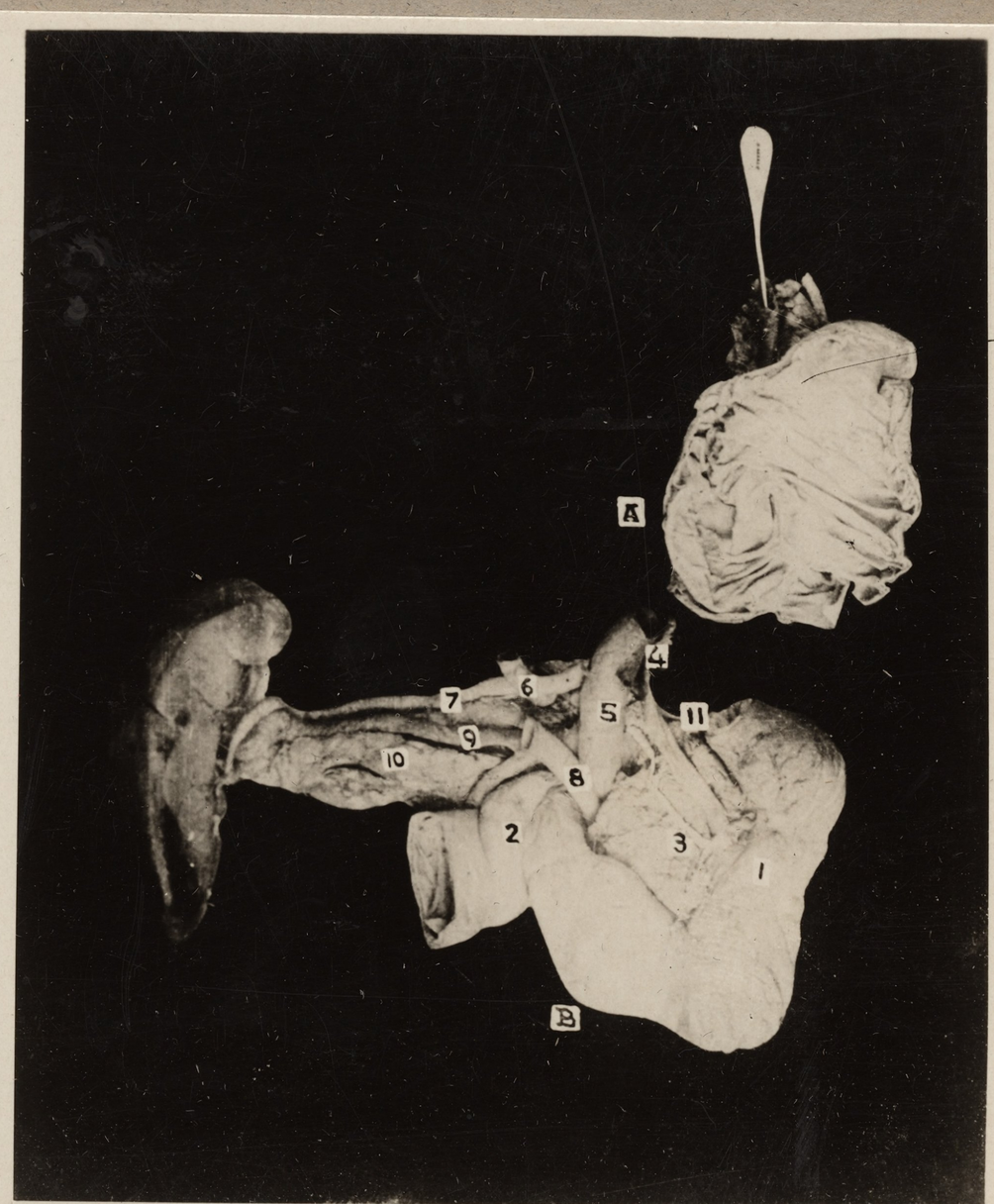
1. Descending part of the duodenum.
2. Duodeno-jejunal flexure.
3. Head of pancreas and pancreatic duct.
4. Common bile-duct.
5. Portal vein.
6. Coeliac axis artery.
7. Splenic artery.
8. Superior mesenteric artery.
9. Splenic vein.
10. Tail of pancreas.
11. Superior pancreatico-duodenal artery.