ABDOMEN.

VISCERA—No. 4.

THE STOMACH VIEWED FROM BEHIND AND BELOW.

The inferior or posterior surface of the stomach, practically entirely invested by peritoneum, forms part of the anterior wall of the lesser peritoneal cavity, and is, therefore, separated by a double layer of peritoneum from the structures with which it is in immediate relation. The only exception is a small triangular area near the cardiac orifice which is in immediate contact with the diaphragm.

The remainder of this surface is in relation with the gastric surface of the spleen, the anterior surface of the left kidney and supra-renal capsule, the pancreas, transverse meso-colon and transverse colon.

The body of the pancreas where it is in front of the vertebral column, causes a marked indentation of this surface, situated near the lesser curvature.

The narrow character of the pyloric orifice should be noted, and also the acute angle which the termination of the oesophagus makes with the stomach.

The figures indicate—

1. Oesophagus.
2. Fundus.
3. Antrum.
4. Lesser curvature.
5. Greater curvature.
6. Pyloric orifice.
7. Pancreatic impression.
8. Impression for the transverse meso-colon.
9. Area for the terminal part of the pancreas.
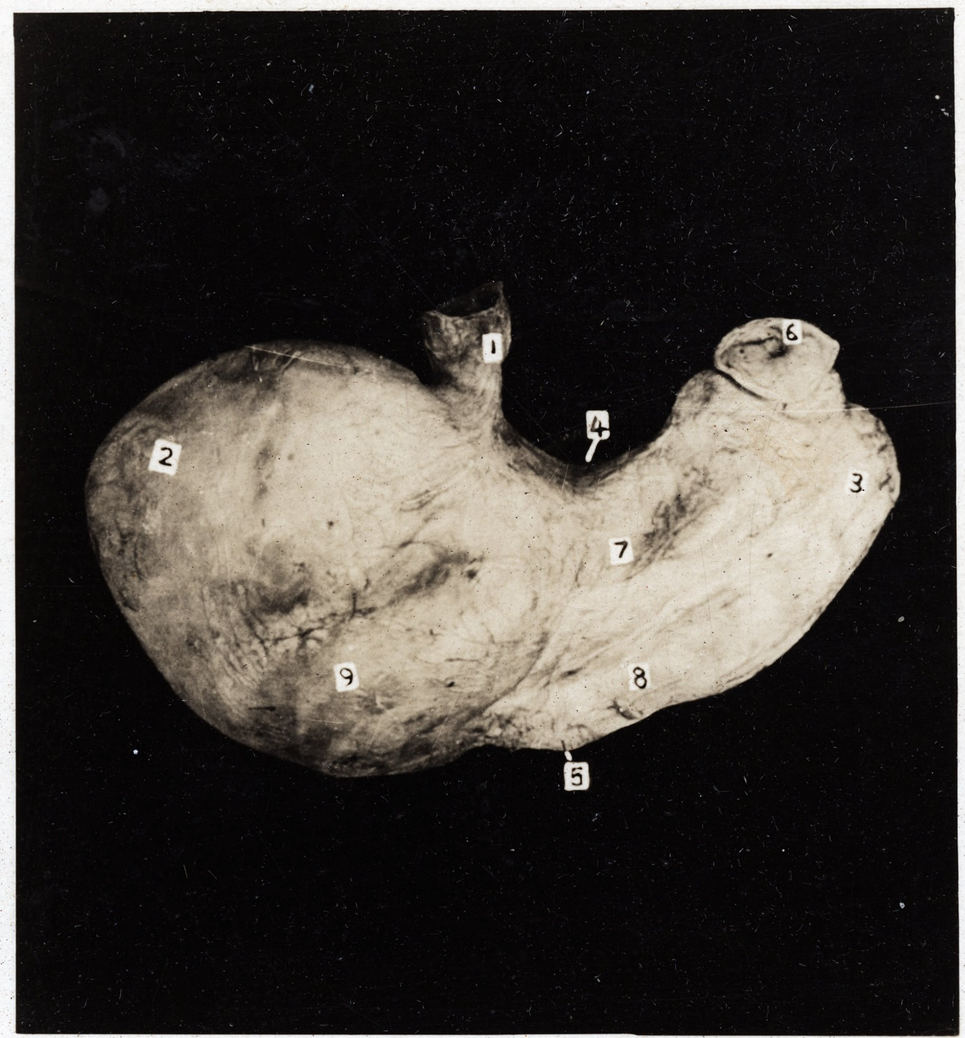
SECTION VI CARD NO. 4