CENTRAL NERVOUS SYSTEM.

BRAIN—No. 2.

BASAL ASPECT OF THE BRAIN.

The Cerebellum, the Pons Varolii, and the Medulla have been removed by cutting through the Mesencephalon. The cut surface of the latter is seen in the middle of the specimen.

GYRI AND SULCI.

1. Calcarine fissure.
2. Isthmus of great limbic convolution.
3. Gyrus lingualis.
4. Collateral sulcus.
5. Hippocampal convolution (note the dentate fissure to its inner side).
6. Uncus (note the groove formed by the edge of the tentorium cerebelli close to the label).
7. Occipito-temporal gyrus.
8. Occipito-temporal sulcus.
9. Inferior temporal gyrus.
10. Groove for the right lateral blood-sinus on the occipital pole.
11. Olfactory sulcus, with gyrus rectus immediately to its inner side.
12. Internal orbital gyrus.
13. Anterior orbital gyrus.
14. Posterior orbital gyrus.
15. External orbital gyrus.

N.B.—Note the H-shaped orbital sulcus which separates these orbital gyri from each other.

OTHER STRUCTURES.

16. Splenium of corpus callosum.
17. Pineal body.
18. In front of label is seen the under surface of the posterior commissure.
19. Crusta of crus cerebri.
20. Substantia nigra.
21. Red nucleus in tegmentum of crus cerebri.
22. Tegmentum of crus cerebri.
23. Under surface of pulvinar of optic thalamus.
24. In front of label is seen the locus perforatus posticus.
25. Corpora albicantia or mammillaria.
26. Tuber cinereum.
27. Optic tract.
28. Optic chiasma, immediately behind which is the infundibulum.
29. Locus perforatus anticus.
30. Olfactory tract and olfactory bulb.

Card 12
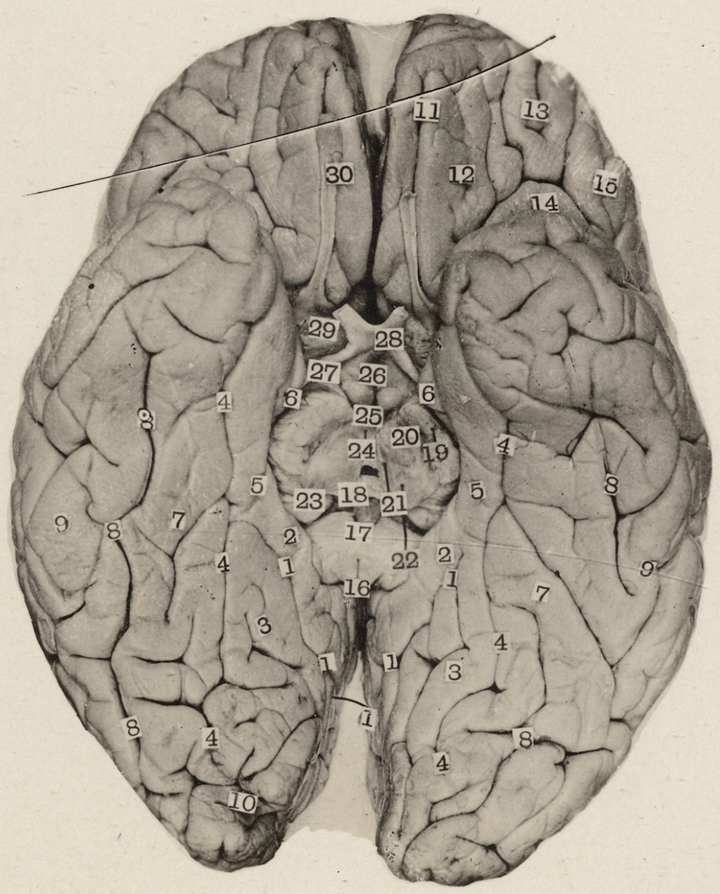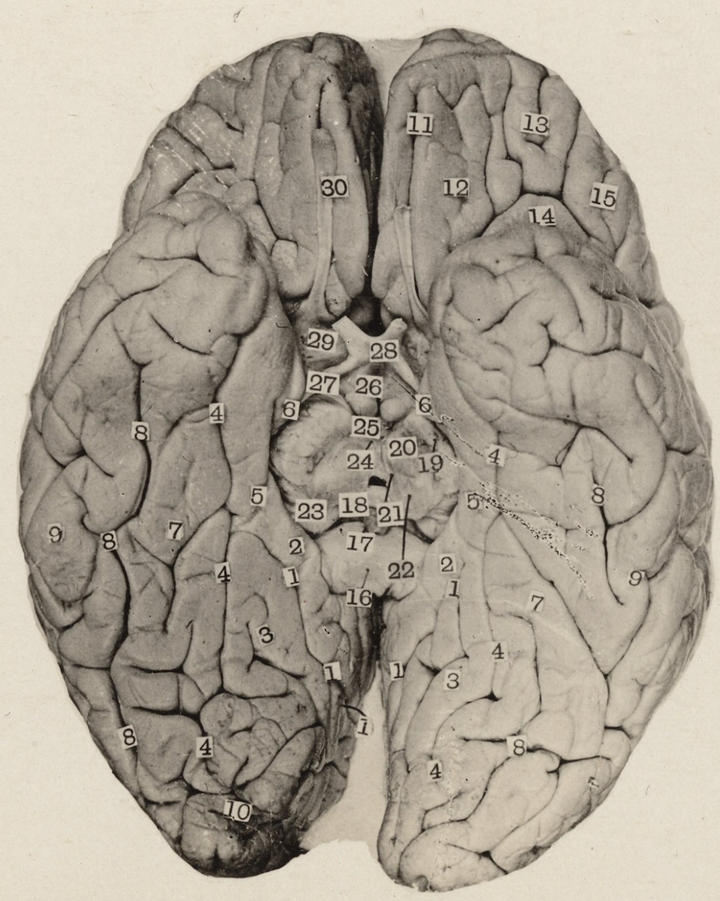
Section I